

Shock wave therapy induces neovascularization at the tendon–bone junction A study in rabbits

Ching-Jen Wang^a, Feng-Sheng Wang^b, Kuender D. Yang^{b,*}, Lin-Hsiu Weng^a,
Chia-Chen Hsu^a, Chun-Shun Huang^c, Lin-Cheng Yang^d

^a Department of Orthopaedic Surgery, Chang Gung Memorial Hospital at Kaohsiung, 123 Ta-Pei Road, Niao-Sung Hsiang, Kaohsiung 833, Taiwan

^b Department of Medical Research, Chang Gung Memorial Hospital at Kaohsiung, 123 Ta-Pei Road, Niao-Sung Hsiang, Kaohsiung 833, Taiwan

^c Department of Pathology, Chang Gung Memorial Hospital at Kaohsiung, 123 Ta-Pei Road, Niao-Sung Hsiang, Kaohsiung 833, Taiwan

^d Department of Anesthesiology, Chang Gung Memorial Hospital at Kaohsiung, 123 Ta-Pei Road, Niao-Sung Hsiang, Kaohsiung 833, Taiwan

Received 21 November 2002; accepted 7 April 2003

Abstract

Despite the success in clinical application, the exact mechanism of shock wave therapy remains unknown. We hypothesized that shock wave therapy induces the ingrowth of neovascularization and improves blood supply to the tissues. The purpose of this study was to investigate the effect of shock wave therapy on neovascularization at the tendon–bone junction. Fifty New Zealand white rabbits with body weight ranging from 2.5 to 3.5 kg were used in this study. The right limb (the study side) received shock wave therapy to the Achilles tendon near the insertion to bone. The left limb (the control side) received no shock wave therapy. Biopsies of the tendon–bone junction were performed in 0, 1, 4, 8 and 12 weeks. The number of neo-vessels was examined microscopically with hematoxylin–eosin stain. Neovascularization was confirmed by the angiogenic markers including vessel endothelial growth factor (VEGF) and endothelial nitric oxide synthase (eNOS) expressions and endothelial cell proliferation determined by proliferating cell nuclear antigen (PCNA) expression examined microscopically with immunohistochemical stains. The results showed that shock wave therapy produced a significantly higher number of neo-vessels and angiogenesis-related markers including eNOS, VEGF and PCNA than the control without shock wave treatment. The eNOS and VEGF began to rise in as early as one week and remained high for 8 weeks, then declined at 12 weeks; whereas the increases of PCNA and neo-vessels began at 4 weeks and persisted for 12 weeks. In conclusion, shock wave therapy induces the ingrowth of neovascularization associated with early release of angiogenesis-related markers at the Achilles tendon–bone junction in rabbits. The neovascularization may play a role to improve blood supply and tissue regeneration at the tendon–bone junction.

© 2003 Orthopaedic Research Society. Published by Elsevier Ltd. All rights reserved.

Keywords: Shock wave therapy; Neovascularization; Angiogenesis; eNOS; VEGF; PCNA; Tendon–bone junction

Introduction

In clinical application, extracorporeal shock wave therapy has shown effect in the treatment of certain orthopaedic conditions including non-union of long bone fracture [21,30,32,37,39], calcifying tendonitis of the shoulder [15,27,31,33,42], lateral epicondylitis of the elbow [10,13,24,28,34], proximal plantar fasciitis [6,19,20, 25,29] and Achilles tendonitis [24]. The success

of shock wave therapy in our experiences ranged from 80% for non-unions of long bone fractures [39] to 90% for tendinopathies of the shoulder, elbow and heel [6,13,42]. In patients with calcifying tendonitis of the shoulder, radiographs showed that 58% of the calcium deposits were completely eliminated after shock wave therapy [42]. In addition, the short-term results of shock wave therapy for avascular necrosis of the femoral head appeared encouraging [16]. Shock wave therapy also showed a positive effect in promoting bone healing in animal experiments [8,9,11,12,18,22,40,44,46].

Despite the success in clinical application, the exact mechanism of shock wave therapy remains unknown. In

* Corresponding author. Tel.: 1886-7-733-5279; fax: +886-7-733-5515.

E-mail address: w281211@adm.cgmh.org.tw (K.D. Yang).

fracture non-unions, it was speculated that shock wave therapy produces micro-fracture which in turn causes hematoma formation and subsequent callus formation and eventual fracture healing [7,11,14,22]. For tendinopathy, it was postulated that shock wave therapy provokes painful level of stimulation, and relieves pain due to tendinopathy at the tendon-bone junction by hyper-stimulation analgesia [14,17,22,23,26,28,33,34,37]. However, there were insufficient data to support either theory. The results of our experiments in dogs demonstrated that shock wave therapy enhanced neovascularization at the tendon-bone junction [41]. Neovascularization was reported to be in association with painful tendinosis and may be responsible for pain in chronic Achilles tendinosis [3,25]. However, we speculated that the reasons for the dissolution of calcium deposits after shock wave therapy in calcifying tendinitis of the shoulder may involve a molecular mechanism of absorption due to improved blood supply. We further hypothesized that shock wave therapy may have the potential to induce the ingrowth of neovascularization and improvement of blood supply that lead to tissue regeneration. The purpose of this study was to investigate the effect of shock wave therapy on neovascularization at the tendon-bone junction of the Achilles tendons in rabbits.

Materials and methods

Animals and shock wave treatment

This study was approved by the Institutional Review Board, and was performed under the guidelines and care of animals in research. Fifty New Zealand white rabbits with body weight ranging from 2.5 to 3.5 kg were used in this study. The right limb received shock wave therapy to the Achilles tendon near the insertion site to the heel bone, and was designated as the study side. The left limb received no shock wave therapy, and was designated as the control side.

The rabbit was anesthetized with ketamine (50 mg/kg) and plexonarbital (30 mg/kg) for the purpose of receiving shock wave application. The rabbit was placed in prone position with the right heel up. The shock wave tube was focused on the Achilles tendon near the insertion site to the heel bone, and the depth of the treatment was determined by the control guide and confirmed with C-arm image. Surgical lubricate was applied to the area of skin in contact with the shock wave tube. Each of the study limb received 500 impulses of shock waves at 14 kV (equivalent to 0.12 mJ/mm²) in 30 min to the right Achilles tendon near the insertion site. The shock wave dosage so selected was based on the experience of our previous animal studies [41,42,44]. Immediately after shock wave therapy, the right limb was checked for swelling, edema, hemorrhage and motion of the limb. No special protection on the right limb or restriction of activities was provided. The rabbit was returned to the housing cage and was cared for by a veterinarian.

Histomorphological assessment

Biopsies of the Achilles tendon-bone units were performed in 0, 1, 4, 8 and 12 weeks with 10 rabbits at each time interval. The first biopsy was obtained in 24 h after shock wave therapy. The specimens were fixed in 4% buffered paraformaldehyde for 48 h and decalcified in PBS-buffered 10% EDTA. Decalcified specimens were longitudinally cut into 5- μ m sections and transferred to poly-lysine-coated slides. The

number of blood vessels including capillaries and muscularized vessels were examined microscopically, and quantitatively assessed in six areas of tendon-bone junction from three sections of the biopsy specimens. A professional pathologist blinded to the treatment regimen performed the measurements on all sections under 40 \times magnification.

Immunohistochemistry

For the purpose of confirming neovascularization, the angiogenic markers including vessel endothelial growth factor (VEGF) and endothelial nitric oxide synthase (eNOS) were examined microscopically with immunohistochemistry stains to reflect the mediators for neovascularization [5,35]. Detection of proliferating cell antigen (PCNA) was chosen to reflect endothelial cell replication [19]. Immunoreactivity in specimens was demonstrated using horseradish peroxidase (HRP)-3 \times , 3,3'-diaminobenzidine (DAB) cell and tissue staining kit (R&D Systems, Inc. Minneapolis, MN, USA) in accordance with manufacturer's instructions. After blocking endogenous peroxidase and non-specific binding, sections were incubated overnight with the antibodies at 4 $^{\circ}$ C. Polyclonal antibodies used for immunohistochemistry were anti-eNOS, anti-VEGF and anti-PCNA (Upstate Biotechnology, Lake Placid, NY, USA). Sections were further incubated with biotinylated anti-goat IgG and then incubated with streptavidin conjugated to HRP. Immunoreactivity was determined by incubating the sections in a chromogen solution containing DAB and 0.1% hydrogen peroxide in the dark, followed by counterstaining with hematoxylin. Dehydrate sections were mounted with mounting medium. Those without primary antibodies were enrolled as negative controls for the immunostaining. Vessels showing positive VEGF expression and cells displaying positive PCNA and eNOS expressions were counted microscopically. The numbers with positive expression were quantitatively assessed, and the averages were calculated from six areas of tendon-bone junction selected from three sections of each biopsy specimen.

Statistical analysis

Data were presented as mean \pm standard error. The numbers of vessels and cells displaying positive angiogenic markers at each time interval between the study side and the control side were compared statistically using Mann-Whitney test with statistical significance at $p < 0.05$.

Results

Increase of neo-vessels after shock wave treatment

The results of neo-vessels of the study and the control sides are summarized in Table 1. In the study side, a significant increase of neo-vessels was noted in 4 weeks, and the increase in neo-vessels persisted until 12 weeks, whereas no increase of neo-vessels was noted in the control side, and the difference in the number of neo-vessels was statistically significant. The microscopic features of neo-vessels of the study and the control sides are shown in Fig. 1. It appeared that formation of neo-vessels after shock wave therapy was time dependent starting in 4 weeks after treatment and it lasted for 12 weeks or longer.

Increase of angiogenic markers after shock wave therapy

The results of angiogenesis-related markers including eNOS, VEGF and PCNA are summarized in Table 2. In the study side, a significant increase in eNOS, VEGF

Table 1
The effect of shock wave therapy on the ingrowth of neo-vessels

Time	Control (N = 50)	Shock wave (N = 50)	P-value ^a
<i>0-Week (N = 10)</i>			
Mean ± SD	22 ± 3	24 ± 4	0.93
<i>1-Week (N = 10)</i>			
Mean ± SD	24 ± 4	26 ± 5	0.95
P-value ^b	0.86	0.92	
<i>4-Week (N = 10)</i>			
Mean ± SD	22 ± 5	42 ± 4	0.024
P-value ^b	0.71	0.0017	
<i>8-Week (N = 10)</i>			
Mean ± SD	24 ± 5	40 ± 5	0.021
P-value ^b	0.82	0.0025	
<i>12-Week (N = 10)</i>			
Mean ± SD	25 ± 6	42 ± 4	0.017
P-value ^b	0.92	0.0082	

P-values are based on Mann-Whitney test: (*) comparison of control with shock wave therapy; (**) comparison of 0-week with 1-, 4-, 8- and 12-week.

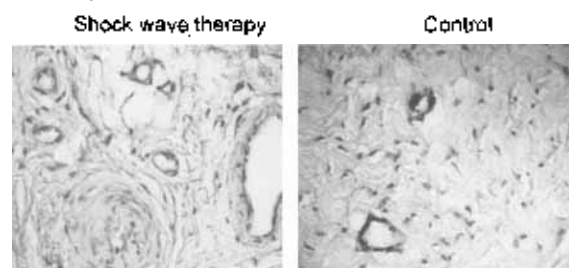


Fig. 1. Tissue biopsies taken from the tendon bone junction were subject to histomorphological staining after decalcification. The neo-vessels on microscopy were examined with 40 \times magnification with the study side on the left, and the control side on the right.

and PCNA was noted in as early as one week. The increase of eNOS and VEGF lasted for 8 weeks before they declined to normal at 12 weeks, whereas the increase of PCNA lasted until 12 weeks. In the control side, however, no significant changes were noted in eNOS, VEGF and PCNA, and the differences between the study and control sides are statistically significant. The microscopic features of eNOS, VEGF and PCNA expressions of the study and the control sides are shown in Fig. 2. The changes in eNOS, VEGF and PCNA expressions at different time intervals are graphically illustrated in Fig. 3. The results of this study demonstrated that shock wave therapy induces early expressions of eNOS, VEGF and PCNA in one week, and subsequent ingrowth of neo-vessels in approximately 4 weeks. The increases of eNOS and VEGF were transient and only lasted for 8 weeks; whereas the stimulation of cell proliferation and the ingrowth of new vessels persisted for 12 weeks and longer. The biological responses after shock wave therapy appear to be time-dependent.

Table 2
Comparison of eNOS, VEGF and PCNA expressions between the study and control sides

Time	Control (N = 50)	Shock wave (N = 50)	P-value
<i>0-Week (N = 10)</i>			
eNOS	112 ± 19	104 ± 21	0.57
VEGF	14 ± 3	12 ± 4	0.94
PCNA	145 ± 31	132 ± 24	0.75
<i>1-Week (N = 10)</i>			
eNOS	124 ± 21	293 ± 31	<0.001
VEGF	17 ± 4	33 ± 5	0.0068
PCNA	155 ± 37	332 ± 28	0.021
<i>4-Week (N = 10)</i>			
eNOS	131 ± 24	344 ± 32	<0.001
VEGF	14 ± 5	36 ± 6	0.0018
PCNA	134 ± 38	320 ± 32	0.011
<i>8-Week (N = 10)</i>			
eNOS	138 ± 26	365 ± 45	0.016
VEGF	15 ± 4	28 ± 4	0.024
PCNA	167 ± 33	312 ± 36	0.024
<i>12-Week (N = 10)</i>			
eNOS	136 ± 21	189 ± 42	0.71
VEGF	17 ± 5	16 ± 4	0.54
PCNA	154 ± 21	280 ± 28	0.034

P-values are based on Mann-Whitney test; P-value: Comparison of the control with the shock wave therapy.

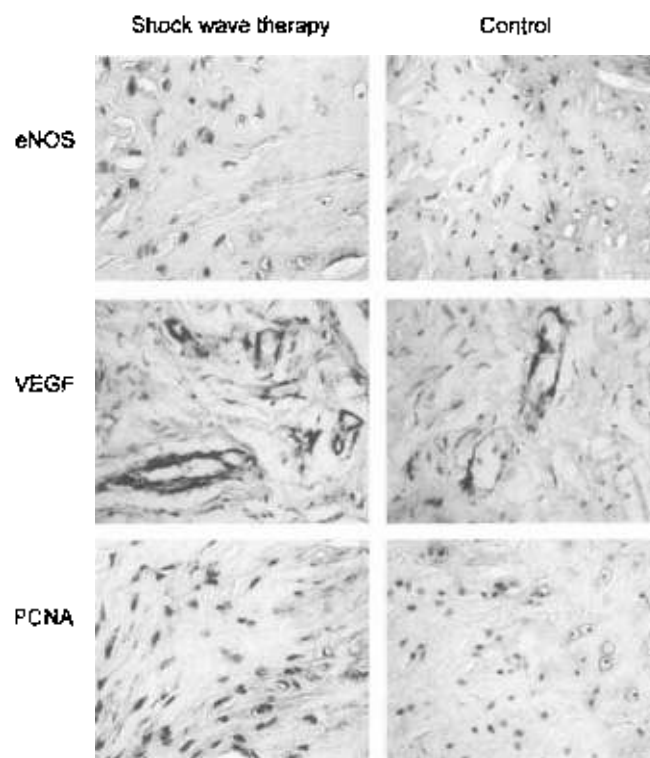


Fig. 2. Tissue biopsies from the tendon bone junction were stained with mouse anti-human eNOS, VEGF and PCNA antibodies respectively, and followed by HRP-conjugated goat anti mouse antibody staining. The results were examined under microscopy with 40 \times magnification with the study on the left, and the control on the right.

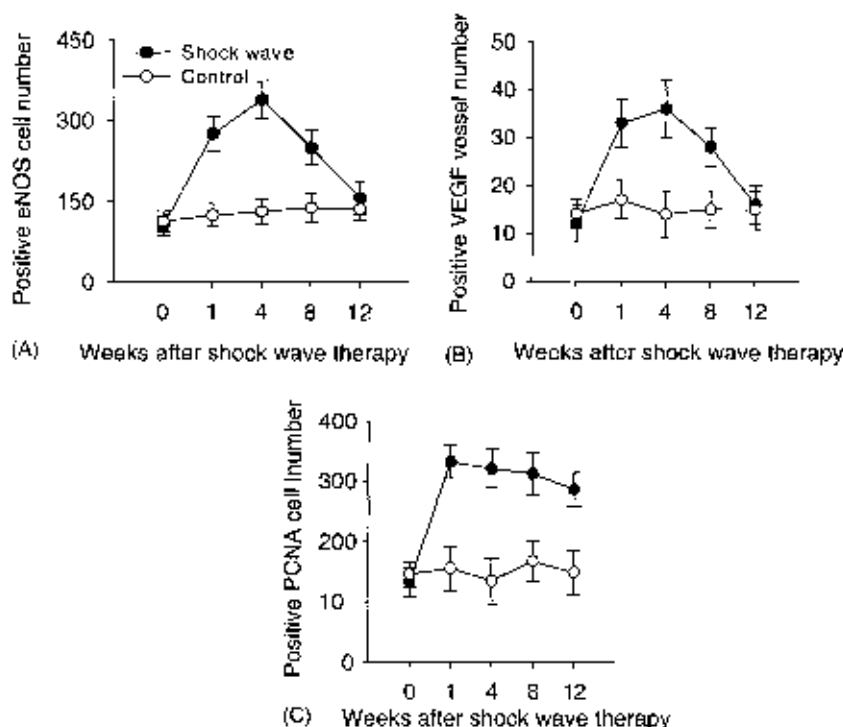


Fig. 3. The changes of eNOS, VEGF, and PCNA at different time intervals after shock wave therapy are shown graphically.

Discussion

Many authors had studied the mechanism of shock wave therapy [7–9,11,12,14,17,18,22–24,26,28,33,34,36,38,40,41,43–46]. Some speculated that shock wave therapy relieves pain due to insertional tendinopathy by hyper-stimulation analgesia [14,22–24,28,37], while others hypothesized the theoretical mechanism of shock wave therapy in bone healing including micro-disruption of avascular or minimally vascular tissue to encourage revascularization and the recruitment of appropriate stem cells conducive to more normal bone tissue healing [11,12,14,18,22,43–46]. However, there are insufficient data to scientifically substantiate either theory concerning the mechanism of shock wave therapy in musculoskeletal disorders.

The etiologies of tendonitis are multi-factorial including degenerative changes, inflammatory process and metabolic disturbance with hypo-vascularity, neuronal origin as well as neovascularization in tendinosis [1–4,24,25]. Neovascularization was found to be in close relation to the area of tendinosis that corresponded to the painful area during Achilles loading. Therefore, neovascularization, rather than a “healing response”, was thought to be responsible for the pain in the area with chronic Achilles tendinosis [3,25]. On the contrary, neovascularization, a direct effect of angiogenic factors secondary to extracorporeal shock wave therapy was found to be responsible for improvement in symptoms of plantar fasciitis [33,34]. In calcifying

tendonitis of the shoulder, shock wave therapy not only provides pain relief, it also eliminates calcium deposits [15,26,27,42]. The mechanical forces of shock wave therapy may theoretically cause fragmentation, but not total absorption of the calcium deposits. Therefore, it is reasonable to assume that a biological process through a molecular mechanism of absorption may take place to dissolve the calcium deposits after shock wave therapy. Nitric oxide and VEGF had been demonstrated as important mediators of angiogenesis [5,35]. We suggest that physical shock waves could raise the mechanotransduction of the tissue to convert acoustic shock wave energy into biological signals. The results of this study showed that shock wave therapy induces the ingrowth of neo-vessels and tissue proliferation associated with the early release of angiogenesis-related factors including eNOS and VEGF at the tendon–bone junction in rabbits. Therefore, the mechanism of shock wave therapy appears to involve the early release of angiogenic growth factors in one week, and induces cell proliferations and formation of neo-vessels in approximately four weeks at the tendon–bone junction. The neovascularization may lead to the improvement of blood supply and play a role in tissue regeneration at the tendon–bone junction. No adverse effect of neovascularization on rabbits was observed during the course of this study.

In non-unions of long bone fractures, the fracture sites are generally filled with dense, hypo-vascular fibrous tissues that prevent the fractures from bony

union. Many studies in animal experiments had demonstrated that shock wave therapy can promote bone marrow stromal cell differentiation toward osteoprogenitors associated with induction of TGF- β 1 and induces membrane hyperpolarization and Ras activation to act as an early signal for the osteogenesis in human bone marrow stromal cells [36,43–46]. Other studies also showed a positive effect of shock wave therapy in promoting bone healing in animal experiments [8,11,12,18]. The results of this study showed that shock wave therapy promotes early release of angiogenic factors, and subsequently induces cell proliferations and ingrowth of neo-vessels that in turn may stimulate the stromal cell growth and differentiation and promote bone healing.

In conclusion, shock wave therapy induces the ingrowth of neovascularization and cell proliferation associated with earlier release of angiogenic growth factors at the tendon bone junction of the Achilles tendon in rabbits. It appears that the mechanism of shock wave therapy involves the early release of angiogenic growth factors (eNOS and VEGF) and subsequent induction of neovascularization and tissue proliferation. The neovascularization may play a role in pain relief of tendinitis and the repair of chronically inflamed tendon tissues at the tendon bone junction.

Acknowledgements

The study was supported by a grant from Chang Gung Research Fund (CMRP 905). No benefits in any form have been received or will be received from a commercial party related directly or indirectly to the subject of this article.

References

- Ackerman PW, Jinn L, Finn A, Ahmed M, Kreibergs A. Autonomic innervation of tendons, ligaments and joint capsules: A morphologic and quantitative study in the rat. *J Orthop Res* 2001;19:372–8.
- Ackerman PW, Ahmed M, Kreibergs A. Early nerve regeneration after Achilles tendon rupture—a prerequisite for healing. A study in the rat. *J Orthop Res* 2002;20:849–56.
- Alfredson H, Bjur D, Teisen K, Lorentzon R. High intra-tendinous lactate levels in painful tendinosis. An investigation using microdialysis technique. *J Orthop Res* 2002;20:934–8.
- Acher RS, Bayley JL, Acher CW, et al. Cell and matrix changes associated with pathological calcification of the human rotator cuff tendons. *J Anat* 1993;182:1–11.
- Babuel S, Stewart DJ. Overexpression of endothelial NO synthase induces angiogenesis in a co-culture model. *Cardiovascular Res* 2002;55:190–200.
- Chen HS, Chen HS, Huang TW. Treatment of painful heel syndrome with shock waves. *Clin Orthop* 2001;387:41–6.
- Coleman AJ, Saunders JT. A review of the physical properties and biological effects of the high amplitude acoustic field used in extracorporeal lithotripsy. *Ultrasonics* 1993;31:75–89.
- Dellus M, Deacenu K, Al Dick Y, et al. Biological effect of shockwaves: In vivo effect of high-energy pulses on rabbit bone. *Ultrason Med Biol* 1995;21:1219–25.
- Forriol T, Salehaga L, Moreno JJ, et al. The effect of shock waves on mature and healing cortical bone. *Int Orthop* 1994;18:325–9.
- Hammer DS, Rupp S, Ensslin S, et al. Extracorporeal shock wave therapy in patients with tennis elbow and painful heel. *Arch Orthop Trauma Surg* 2000;120:204–7.
- Haupt G, Haupt A, Bekermkamp A, et al. Influence of shockwave on fracture healing. *J Urol* 1993;39:529–32.
- Johannes EJ, Kauderer-Sukul DM, Metzger E, et al. High-energy shock waves for the treatment of nonunions: An experiment on dogs. *J Surg Res* 1994;57:246–54.
- Ko JY, Chen HS, Chen LM. Treatment of lateral epicondylitis of the elbow with shock waves. *Clin Orthop* 2001;387:60–7.
- Lingeman JE, McAteer JA, Kempson SA, et al. Bioeffects of extracorporeal shock-wave lithotripsy: Strategy for research and treatment. *Urol Clin North Am* 1998;15:507–14.
- Loew M, Duecke W, Kuzniertzak D, et al. Shock-wave therapy is effective for chronic calcifying tendinitis of the shoulder. *J Bone Joint Surg* 1999;81B:663–7.
- Ludwig J, Lauber S, Lauber H-J, et al. High-energy shock wave treatment of femoral head necrosis in rats. *Clin Orthop* 2001; 387:119–26.
- Maier M, Milz S, Wirtz DC, Rompe JD, Schmitz C. Basic research of applying extracorporeal shockwaves on the musculo-skeletal system. An assessment of current status. *Orthopedics* 2002;31:667–77.
- McCarthy D, Lane H, McElwain J. The osteogenic potential of extracorporeal shock wave therapy: An in-vivo study. *Br J Med Sci* 1996;165:20–2.
- Nagashima M, Tanaka H, Takahashi A, Tanaka K, Ishiwata T, Asano G, et al. Study of the mechanism involved in angiogenesis and synovial cell proliferation in human synovial tissues of patients with rheumatoid arthritis using SCID mice. *Lab Invest* 2002;82(8):981–8.
- Ogden JA, Alvarez R, Levitt R, et al. Shock wave therapy for chronic proximal plantar fasciitis. *Clin Orthop* 2001;387:47–59.
- Ogden JA, Alvarez R, Levitt R, et al. Shock wave therapy (Orthotripsy®) in musculoskeletal disorders. *Clin Orthop* 2001; 387:22–40.
- Ogden JA, Toth-Kischkat A, Schultheiss R. Principles of shock wave therapy. *Clin Orthop* 2001;387:8–17.
- Orhan Z, Alper M, Akman Y, Yavuz O, Yalciner A. An experimental study on the application of extracorporeal shock waves in the treatment of tendon injuries. Preliminary report. *J Orthop Sci* 2001;6:566–70.
- Perlick L, Schifmann R, Kretz CN, Walmy T, Diedrich O. Extracorporeal shock wave treatment of the Achilles tendinitis: Experimental and preliminary clinical results. *Z Orthop Ihre Grenzgeb* 2002;140(3):275–80.
- Ohlberg L, Alfredson H. Ultrasound guided sclerosis of neovessels in painful chronic Achilles tendinitis. Pilot study of a new treatment. *Br J Sports Med* 2002;36:173–5.
- Rompe JD, Kirkpatrick CJ, Küllmer K, et al. Dose related effects of shock waves on rabbit tendon Achilles. A sonographic and histological study. *J Bone Joint Surg* 1998;80B:546–52.
- Rompe JD, Burger R, Hopf C, et al. Shoulder function after extracorporeal shock wave therapy for calcific tendinitis. *J Shoulder Elbow* 1998;7:505–9.
- Rompe JD, Hopf C, Küllmer K, et al. Analgesic effect of extracorporeal shock wave therapy on chronic tennis elbow. *J Bone Joint Surg* 1996;78B:233–7.
- Rompe JD, Hopf C, Nale B, et al. Low-energy extracorporeal shock wave therapy for painful heel: A prospective controlled single-blind study. *Arch Orthop Trauma Surg* 1996;115: 75–9.

- [30] Rompe JD, Rosendahl T, Schöllner C, et al. High-energy extracorporeal shock wave treatment of nonunions. *Clin Orthop* 2001;387:102–11.
- [31] Rompe JD, Ruedler F, Hopf C, et al. Extracorporeal shock wave therapy for calcifying tendinitis of the shoulder. *Clin Orthop* 1995;321:196–201.
- [32] Schuden W, Fischer A, Sauter A. Extracorporeal shock wave therapy of nonunion or delayed osseous union. *Clin Orthop* 2001; 387:90–4.
- [33] Speed CA, Richards C, Nichols D, Burnet S, Wiles JT, Humphrey H, et al. Extracorporeal shock wave therapy for tendonitis of the rotator cuff: A double-blind, randomized, controlled trial. *J Bone Joint Surg (Br)* 2002;84:506–12.
- [34] Speed CA, Nichols D, Richards C, Humphrey SH, Wiles JT, Burnet S, et al. Extracorporeal shock wave therapy for lateral epicondylitis: a double-blind, randomized, controlled trial. *J Orthop Res* 2002;20:895–8.
- [35] Spyridopoulos I, Luedeman C, Chen D, Kearney M, Murohara T, Principe N, et al. Divergence of angiogenesis and vascular permeability signaling by VEGF: inhibition of protein kinase C suppresses VEGF-induced angiogenesis, but promotes VEGF-induced NO-dependent vascular permeability. *Arterioscl Thromb Vasc Biol* 2002;22:907–6.
- [36] Sühr D, Brummer P, Ulmer DF. Cavitation-generated free radicals during shock wave exposure: investigations with cell-free solutions and suspended cells. *Ultrasound Med Biol* 1992;17:761–8.
- [37] Thiel M. Application of shock waves in medicine. *Clin Orthop* 2002;387:18–21.
- [38] Vaterlein N, Lussenhop S, Hahn M, Delling G, Meiss AI. The effect of extracorporeal shock waves on joint cartilage – An in vivo study in rabbits. *Acta Orthop Trauma Surg* 2000;120:403–6.
- [39] Wang CJ, Chen HS, Chen CH, et al. Treatment of nonunions of long bone fractures with shock waves. *Clin Orthop* 2001;387:95–101.
- [40] Wang CJ, Huang HY, Chen HH, et al. Effect of shock wave therapy on acute fractures of the tibia. A study in a dog model. *Chin Orthop* 2001;387:112–8.
- [41] Wang CJ, Huang HY, Pui CH. Shock wave therapy enhanced neovascularization at the tendon-bond junction: an experiment in dogs. *J Foot Ankle Surg* 2002;41:16–22.
- [42] Wang CJ, Ko JY, Chen HS. Treatment of calcifying tendinitis of the shoulder with shock wave therapy. *Clin Orthop* 2001;387:83–9.
- [43] Wang FS, Wang CJ, Huang HC, et al. Physical shock wave mediates membrane hyperpolarization and Ras activation for osteogenesis in human bone marrow stromal cells. *Biochem Biophys Res Commun* 2001;287:648–55.
- [44] Wang FS, Yang KD, Wang CJ, et al. Extracorporeal shock wave promotes bone marrow stromal cell growth and differentiation toward osteoprogenitors associated with TGF- β 1 induction. *J Bone Joint Surg* 2002;84B:457–61.
- [45] Wang FS, Wang CJ, Sheen-Chen SM, et al. Superoxide mediates shock wave induction of RRE-dependent osteogenic transcription factor (CBFA-1) and mesenchymal cells differentiation toward osteoprogenitors. *J Biol Chem* 2002;277:10931–7.
- [46] Yang C, Heston WDW, Gulati S, Fair WR. The effect of high-energy shock waves (HESW) on human bone marrow. *Urol Res* 1988;16:427–42.